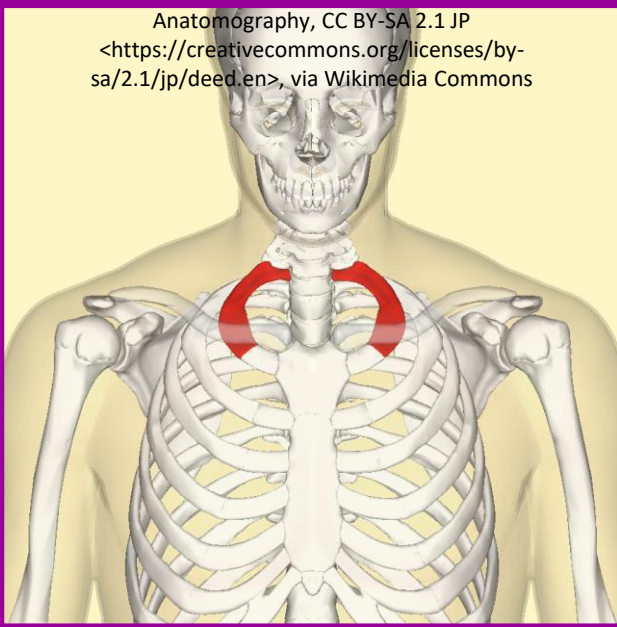
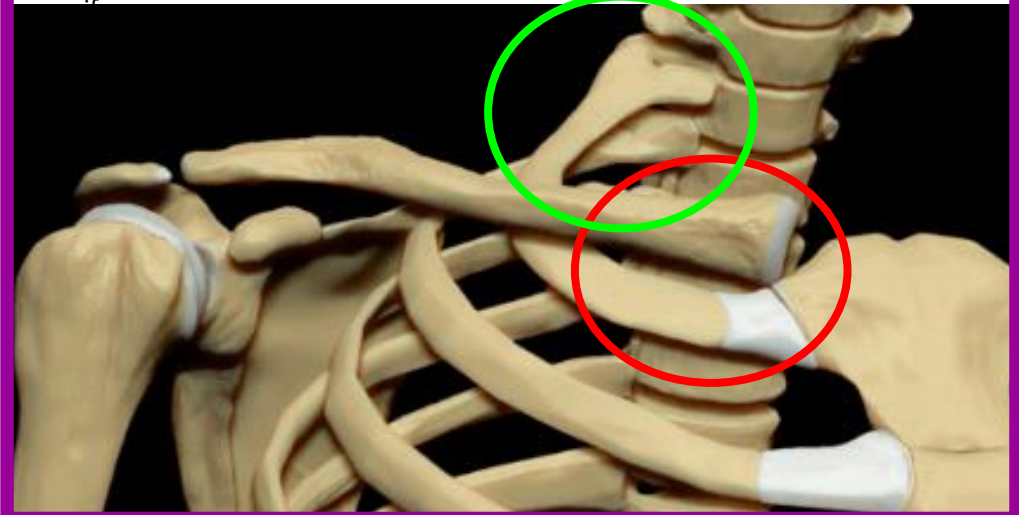


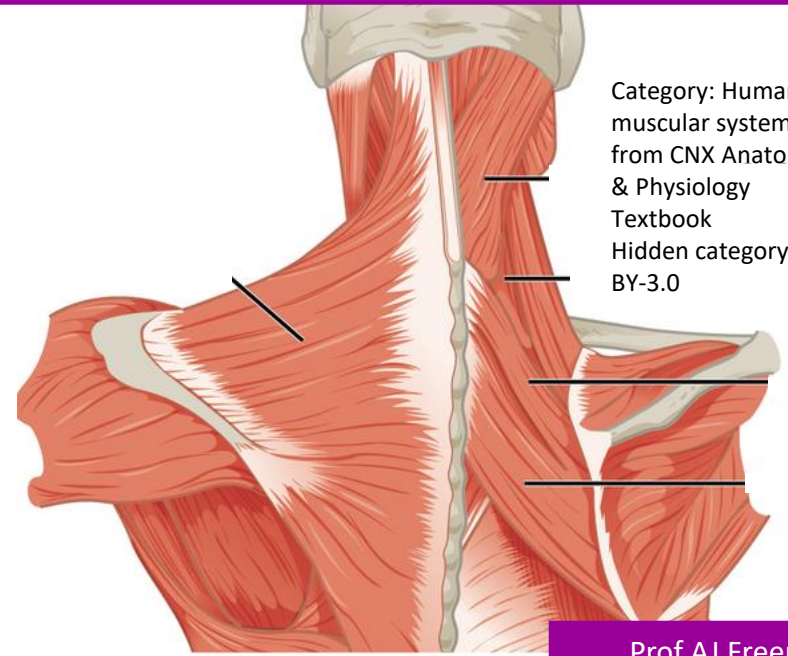
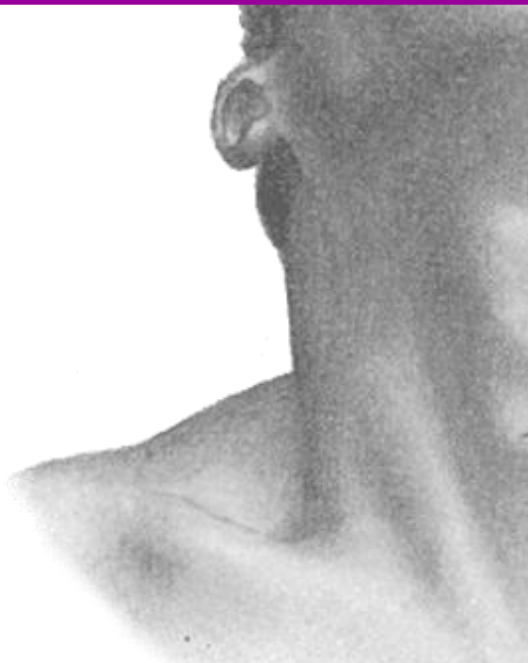Anatomography, CC BY-SA 2.1 JP  
<<https://creativecommons.org/licenses/by-sa/2.1/jp/deed.en>>, via Wikimedia Commons



By DrJanaOfficial - Own work, CC BY-SA 4.0,  
[https://commons.wikimedia.org/wiki/File:Clavicle\\_3d\\_Model](https://commons.wikimedia.org/wiki/File:Clavicle_3d_Model)



Henry Gray (1918)  
Anatomy of the  
Human Body 20<sup>th</sup>  
edition  
Henry Vandyke  
Carter (1831–  
1897)



Category: Human  
muscular system  
from CNX Anatomy  
& Physiology  
Textbook  
Hidden category: CC-  
BY-3.0

Prof AJ Freemont  
University of Manchester